

# Example of an analog workflow

## General Hospital Main Street BREAST ULTRASOUND WORKSHEET

Name Sally Date 9/23/08  
 Referring Physician Dr. Green History none / family

Cyst Identified:  Yes  No How Many?       
 Location & Size     

Complex Mass Identified:  Yes  No  
 Location & Size       
 Description     

Solid Mass Identified:  Yes  No  
 Location & Size small  
 Description wispy small change

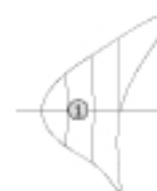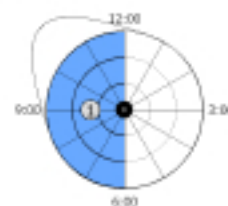


Technologist Initials: SL

# Example of a digital workflow

Annotations: J  
Right Breast

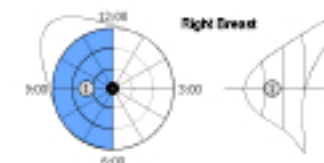
## Work Sheet



Scanned regions are shaded.

① Probable solid (with malignant characteristics)  
 9:00 o'clock, 1.20 cm from skin, 1.40 cm from nipple  
 0.23 x 0.48 cm  
 Oval, not parallel

① Probable solid (with malignant characteristics)  
 9:00 o'clock, 1.20 cm from skin, 1.40 cm from nipple  
 0.23 x 0.48 cm



Scanned regions are shaded.

B-CAD Segmentation B-CAD Optimal Image Goodness of Fit

ACR BI-RADS® US Classification Form, Copyright 2003 ACR

Shape	<b>Irregular</b>	Echo Pattern	--
Orientation	<b>Not Parallel</b>	Calcifications	--
Margin	--	Surrounding Tissue	--
Lesion Boundary	--	Vascularity	--
Posterior	--	Special Cases	--

