

Example of an analog workflow

General Hospital Main Street BREAST ULTRASOUND WORKSHEET

Name Sally Date 9/23/08
 Referring Physician Dr. Green History none / family

Cyst Identified: Yes No How Many?
 Location & Size

Complex Mass Identified: Yes No
 Location & Size
 Description

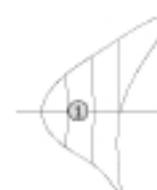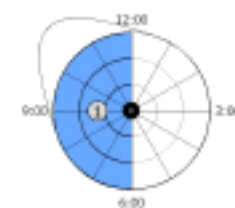
Solid Mass Identified: Yes No
 Location & Size small
 Description wispy small change



Technologist Initials: SL

Example of a digital workflow

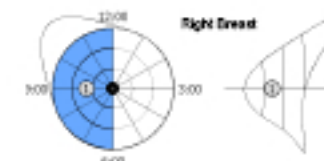
Annotations: J
Right Breast



Scanned regions are shaded.

① Probable solid (with malignant characteristics)
 9:00 o'clock, 1.20 cm from skin, 1.40 cm from nipple
 0.23 x 0.48 cm
 Oval, not parallel, not circumscribed (indistinct), shadowing, hypochoic echo pattern

① Probable solid (with malignant characteristics)
 9:00 o'clock, 1.20 cm from skin, 1.40 cm from nipple
 0.23 x 0.48 cm



Scanned regions are shaded.

B-CAD Segmentation B-CAD Optimal Image Goodness of Fit

ACR BI-RADS® US Classification Form, Copyright 2003 ACR

Shape	Irregular	Echo Pattern	Hypochoic
Orientation	Not Parallel	Calcifications	--
Margin	Not Circumscribed (Indistinct)	Surrounding Tissue	--
Lesion Boundary	--	Vascularity	--
Posterior	Shadowing	Special Cases	--

Series 1 Image 5

Series 1 Image 5

